

CASE REPORT

Management Cataract Complication and Malignant Glaucoma After Vitrectomy Surgery and C3F8 Gas Tamponade

Frisma Sagara Brilliyanto¹, Wimbo Sasono¹

¹ Ophthalmology Department Airlangga University School of Medicine-Dr. Soetomo General Hospital
Jl. Mayjen. Prof. Dr. Moestopo No. 47 Surabaya, Indonesia

Corresponding author : Frisma Sagara Brilliyanto (frismamatal6@gmail.com)

ABSTRACT

Report a clinical presentation of patient with rheumatogenous retinal detachment by vitrectomy and high myopia with C3F8 gas tamponade. A 20-year-old female came into the outpatient clinic with blurry vision on the right eye as her chief complaint. It had been happening since 1 month ago. In examination, we found result of visual acuity RE 1/300 and LE 1/60 correction Sferis-16.00 5/7.5, anterior segment in a normal range. In posterior segment evaluation, there were RE detachment on 3-11 o'clock position and hole on 6 and 8 o'clock position. Then we performed vitrectomy and C3F8 gas tamponade. The first day after surgery, we found IOP 19,6 mmHg and Von Herrick III. Then after the second day, we found a pain on the right eye, TIO 47.3 mmHg, Von Herrick 0 and opaque lens. Then we performed iridectomy and intravitreal gas aspiration. After it were done, we found IOP 17.3 mmHg and Von Herrick 0. In anterior segment OCT evaluation, we found a narrow angle anterior segment. Then we planned to do a cataract extraction with using viscoelastic to perform the anterior chamber. Malignant glaucoma can occur in cases after vitrectomy action due to aqueous misdirection and emphasis on gas expansion on tamponade. Cataract extraction and gas aspiration can help open the anterior chamber and the intraocular pressure returns to normal

Keywords : *Rheumatogenous retinal detachment, Myopia, C3F8 gas tamponade*

INTRODUCTION

Retinal detachment is the term used to describe detachment of the neurosensory retina from the underlying membrane, the retinal pigment epithelium. The separation of the two layers takes place within the fissure formed by the invagination of the optic cup. The most frequent is the rhegmatogenous form of detachment, in which a retinal tear allows liquefied vitreous humor to penetrate under the retina. (Kanclerz P and Grzybowski A. 2108)

Rhegmatogenous retinal detachment (RRD) is the most common type of retinal detachment and is among the main emergency indications in ophthalmology, required immediate management. RRD is the separation of the neurosensory retina from the underlying

retinal pigment epithelium, caused by holes or tears in the retina that allow fluid to flow from the vitreous cavity to the subretinal space and collect underneath the retina, pulling the retina away from underlying tissues. (Shaheed, M and Lai TY, 2016).

Rhegmatogenous retinal detachment (RRD) is a major cause of visual loss. Risk factors for RRD include male gender, a history of trauma, congenital anomalies, cataract extraction and myopia.⁵ Male gender has been found to be a significant risk factor for RD in both adults and children after cataract surgery, and in those without previous cataract surgery. (Drury, B dan Bourke RD, 2010)

Rhegmatogenous retinal detachment (RRD) repair is one of the most common

vitreoretinal surgeries a surgeon performs. In an ideal scenario, RRD can be repaired with a single surgical intervention; however, despite excellent skill, flawless technique, and the introduction of high-end technology, up to 10% of cases require additional interventions to ultimately repair recurrent detachments. The advent of microincision vitrectomy system, perfluorocarbon liquids, and effective intraocular tamponades has opened new doors for managing re-RDs. (Nagpal, M., *et.al* 2018)

From the surgical point of view, retinal detachment in highly myopic eyes differs from emmetropic or low-grade myopic eyes. Because of very long axial length with generalized thinning of the sclera, the potential for muscle avulsion, vortex vein damage, haemorrhage, retained subretinal fluid upon internal drainage, and globe perforation during surgery upon exposure and placing the anchor suture were noted in highly myopic eyes.^{10,17}

The procedures used for surgical management of retinal detachment are scleral buckling and vitrectomy.¹³ This paper reports a case of malignant glaucoma after vitrectomy in patients with rhegmatogenous retinal detachment and high myopia with C3F8 gas tamponade.

CASE REPORT

A 20-year-old female came into the outpatient clinic with blurry vision on the right eye as her chief complaint. It had been happening since 1 month ago. In examination, we found result of visual acuity right eye 1/300 and left eye 1/60 correction Sferis-16.00 5/7.5, Intraocular pressure (IOP) right eye 10,2 mmHg and left eye 14.6 mmHg anterior segment in a normal range. In posterior segment evaluation, there were Right Eye detachment on 3-11 o'clock position and hole on 6 and 8 o'clock position.

Then we performed vitrectomy and C3F8 gas tamponade. The first day after surgery, we found right eye IOP 19,6 mmHg and Von Herrick III. Then after the second day, we found a pain on the right eye, IOP 47.3 mmHg, Von Herrick 0 and opaque lens.

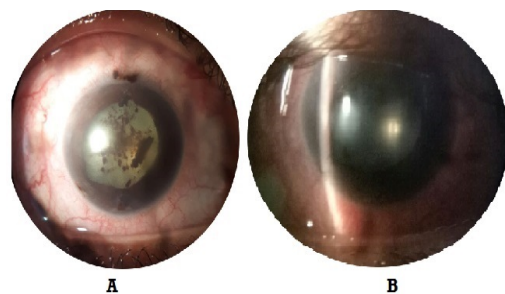


Figure 1 : Preoperative Photograph: A. Cataract complicated with pigment iris. B. Closed angle in anterior chamber

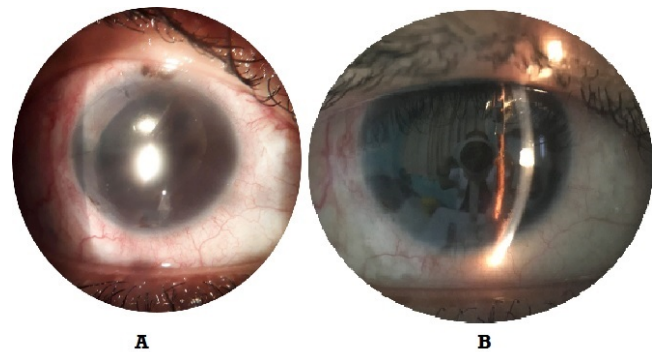


Figure 2 : Postoperative Photograph: A. Post extraction cataract. B. Open angle in anterior chamber

Then we performed iridectomy and intravitreal gas aspiration. After it were done, we found IOP 27.3 mmHg and Von Herrick 0. In anterior segment OCT evaluation, we found a narrow angle anterior segment. Then we planned to do a cataract extraction with using viscoelastic to perform the anterior chamber.

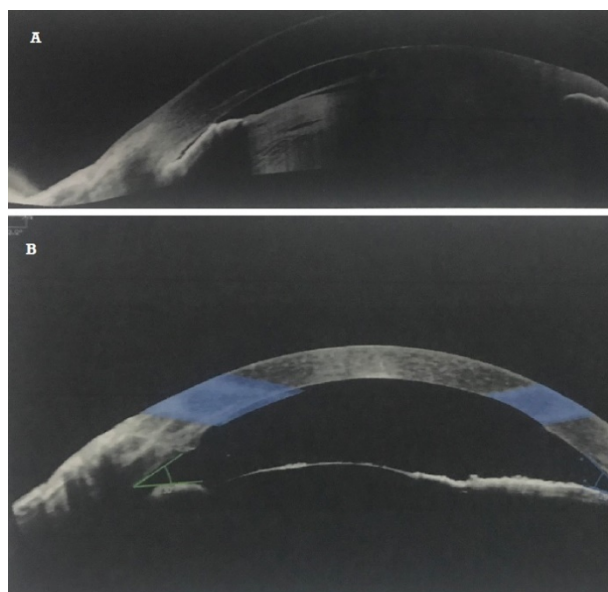


Figure 3: OCT Anterior Segment Photograph:
A. Pre extraction cataract. B. Post extraction
cataract

Discussion

Typically, retinal detachment is treated by sealing all the holes in the retina, performed by operative intervention of scleral buckling or vitrectomy. Pars plana vitrectomy is becoming the procedure of choice for rhegmatogenous retinal detachment. This intervention can be carried out singly or in combination with laser coagulation or cryocoagulation for scar induction. Scar induction by laser coagulation or cryocoagulation is only effective for preventing the release of the retina that is still attached; both forms of coagulation are of no use if detachment has occurred.^{18,22} In these patients vitrectomy is only performed because retina detachment has occurred at the 3-11 hour position and holes in the 6 and 8 o'clock position.

Vitrectomy begins with removing of the vitreous humor causing retinal detachment, followed by displacement subretinal fluid by means of a tamponade. The vitreous is then replaced by tamponade, which holds the retina against the underlying retinal pigment

epithelium until a firm scar forms around the retinal hole.⁹

Intraocular gases are the most common type of tamponade used in vitreoretinal surgery and they are indispensable for that purpose. The advantage of gas tamponade is that it is absorbed and thus does not need to be removed. Because the water solubility is lower than nitrogen, pure sulfur hexafluoride (SF₆), hexafluoroethane (C₂F₆), and perfluoropropane (C₃F₈) will expand when injected into the eye. The volume of SF₆ doubles within 24–48h, whereas C₃F₈ can expand to four times its original volume within 48–72 h. Its surface tension prevents the movement of fluid to the retina, supports physiological removal of fluid from the retinal space and allows chorioretinal adhesion. The disadvantage of gas tamponade is that the mixture expands postoperatively (due to heating and absorption of nitrogen from the blood), with the danger of pressure decompensation. How long the remaining gas in the eye depends on which gas is chosen, how much is injected, and on intraocular pressure. The average gas remains in the eye for between 14 days (SF₆) and 2 months (C₃F₈). The gas tamponade used in the reported patient was C₃F₈ gas tamponade. (Feltgen N, & Walter P. 2014)

The first day after surgery, the reported patient obtained an IOP of 19.6 mmHg and Von Herrick III. Then after the second day, pain in the right eye was found, IOP 47.3 mmHg, Von Herrick 0 and opaque lens. IOP increase in eyes with intraocular tamponade is a common postoperative complication reported in up to 58.9% of eyes. Elevated IOP after vitrectomy may cause optic nerve damage, retinal ischemia, and subsequent visual loss. The mechanism can be open angle, closed angle, or both. In open-angle mechanism, IOP elevation is due to intraocular gas expansion. Closed-angle cases are less common but are

usually a result of anterior displacement of the iris-lens diaphragm and iridocorneal apposition with or without pupillary block.(Mansukhani, S.A., *et.al.*, 2018)

Increased intraocular pressure and progressive glaucoma damage are known as postoperative complications after vitreoretinal surgery. In addition, eyes that require vitreoretinal surgery may already be susceptible to increased pressure. Eyes with primary open angle glaucoma (POAG) experience retinal detachment at a higher rate than normal eyes, and the prevalence of primary open angle glaucoma in eyes with retinal detachment is reported to be 4-12 times higher than the general population. Although it is not clear why primary open angle glaucoma predisposes to retinal detachment, the prevalence of myopia as a common risk factor for both disorders [3] and the use of myotics in the treatment of glaucoma that results in retinal detachment has been suggested as a possible explanation. In addition, glaucoma can occur as a direct consequence of surgical repair of retinal detachment.(Siegfried, C.J., and Shui, Y.B. 2019)

In addition, the increase in IOP is also directly related to the expansive nature and final volume of intraocular gas bubbles. Expansive gas bubbles cause iridocorneal apposition without pupillary block glaucoma, or angular closure with pupillary block, which would require removal of the gas bubble. Based on the description, to overcome malignant glaucoma in these patients performed iridectomy and intravitreal gas aspiration.(Liao, L., and Zhu, X.H. 2019)

Cataract is a common complication of vitreoretinal surgery, which develops due to inhibited diffusion of nutrients impeding proper lens metabolism. Exposure to intraocular gases additionally increases retrolental oxygen levels, resulting in

development of lens opacities. Lens opacities appear to have occurred in the reported patient.(Kanclerz P and Grzybowski A. 2108)

After iridectomy and intravitreal gas aspiration in these patients, IOP was found 17.3 mmHg and Von Herrick 0. In the evaluation of the anterior segment OCT, a narrow angle anterior segment was obtained. In narrow angle glaucoma, IOP reduction has been shown to be substantial by lens extraction (56-79%), and very few require postoperative IOP-lowering drugs.²³ Based on this, cataract extraction was carried out using viscoelasticity in these patients, to deepen the anterior chamber. After extraction of cataracts and viscoelastic intracameral visual acuity RE 1/60 with an IOP of 10.2 mmHg and Von Herrick 3 with anterior OCT, the anterior segment of the eye is open

Reference

- Drury, B dan Bourke RD, 2010. Short-term intraocular tamponade with perfluorocarbon heavy liquid, *Br J Ophthalmol*, Vol.95: pp. 694- 698.
- Feltgen N, & Walter P. (2014). Rhegmatogenous retinal detachment--an ophthalmologic emergency. *Deutsches Arzteblatt international*, Vol.111(1-2): pp 12–22.
- Heiman, H, Stappler, 2008. Heavy tamponade : a review of indication, use, and complications. *Eye*. Vol.22: pp. 1342-1359
- Kanclerz P and Grzybowski A. 2108. Complications Associated with the Use of Expandable Gases in Vitrectomy. *Journal of Ophthalmology*, Vol. 2018, Article ID 8606494, 7 pages.
- Kim MS, Park SJ, Park KH, and Woo SJ. 2019. Different Mechanistic Association

- of Myopia with Rhegmatogenous Retinal Detachment between Young and Elderly Patients, *BioMed Research International*, Article ID 5357241, 6 pages.
- Liao L & Zhu XH. 2019. Advances in the treatment of rhegmatogenous retinal detachment. *International journal of ophthalmology*, Vol. 12(4): pp 660–667.
- Ling, J. D., & Bell, N. P. 2018. Role of Cataract Surgery in the Management of Glaucoma. *International ophthalmology clinics*, Vol.58(3): pp. 87–100.
- Nagpal, M., Chaudhary, P., Wachasundar, S., Ettayib, A., and Raihan, A. 2018. Management of Recurrent Rhegmatogenous Retinal Detachment. *Indian Journal Of Ophthalmology*. Volume: 66 Page 1763-1771.
- Shaheed, M and Lai TY, 2016 Intraocular gas in vitreoretinal surgery, *KJ Ophthalmol*, Vol 14 no.1: pp. 8-14.
- Siegfried, C.J., and Shui, Y.B. 2019. Intraocular Oxygen and Antioxidant Status: New Insights on the Effect of Vitrectomy and Glaucoma Pathogenesis. *American Journal of Ophthalmology*. [July 2019](#) Volume 203, Pages 12–25.
- Stene-Johansen I., Bragadóttir R., Petrovski, BÉ., & Petrovski, G. (2019). Macular Hole Surgery Using Gas Tamponade-An Outcome from the Oslo Retrospective Cross-Sectional Study. *Journal of clinical medicine*, Vol.8(5); pp 704.
- Vichare, Lt Col Nitin, and Bhargava, Col N. Waardenburg syndrome: A rare case with bilateral congenital cataract: An unusual entity. *Medical journal armed forces india*. 2013, 69,172-174.